

# A Head-to-Head Comparison Among Donor Site Morbidity After Vascularized Lymph Node Transfer: Pearls and Pitfalls of a 6-Year Single Center Experience

PEDRO CIUDAD, MD, PhD,\* OSCAR J. MANRIQUE, MD, SHIVPRASAD DATE, MD,  
BULENT SACAĞ, MD, WEI-LING CHANG, BS, KIDAKORN KIRANANTAWAT, FRCS(T), MD,  
SEONG YOON LIM, MD, AND HUNG-CHI CHEN, MD, PhD

Department of Plastic and Reconstructive Surgery, China Medical University Hospital, Taichung, Taiwan

Between 2010 and 2016, 110 patients with extremity lymphedema underwent vascularized lymph node (VLN) transfer: groin (G-VLN = 20), supraclavicular (SC-VLN = 54), and right gastroepiploic (RGE-VLN = 36) open and laparoscopic approach. Herein, we discuss the pearls and pitfalls for VLN harvest and compare donor site morbidity and complications. Lymphatic leakage: G-VLN (n = 1) and SC-VLN (n = 1) and one hematoma: SC-VLN were found. Laparoscopic harvest of the RGE-VLN reduces donor site morbidity. However, surgeons experience is imperative to minimize donor site morbidity and complications.

*J. Surg. Oncol.* © 2016 Wiley Periodicals, Inc.

**KEY WORDS:** lymphedema; donor site morbidity; lymph node flap transfer; vascularized lymph node transfer; lymphaticovenous anastomosis

## INTRODUCTION

Vascularized lymph node (VLN) transfer has shown promising results in the microsurgical management for extremity lymphedema [1–4]. During the last decade, search for the least invasive technique and with a reduced number of donor site complications, has challenged the surgeon to explore more surgical techniques in VLN transfer surgery [5–12]. However, there are still some concerns regarding donor site morbidity following VLN harvest [13–19].

After transferring VLNs there is always a risk to develop lymphedema, lymphorrhea, or other unexpected complications at the donor site [17–19]. Even though the knowledge for the surgical treatment of lymphedema has increased and several VLN flaps have been described, currently, there are no reports comparing different donor sites for VLN transfer with long-term outcomes and follow-up from a single center experience.

Herein, we present our experience with three different lymph node flaps used for the treatment of patients with extremity lymphedema. The aim of this study is to compare donor site morbidity and complications after VLN transfer with the most common flaps used in our department in the past 6 years. In addition, we will discuss the pearls and pitfalls for flap harvest that we have been using in order to avoid potential complications and improve final outcomes.

## MATERIALS AND METHODS

This is an institutional retrospective review of a prospective maintained database based of a single surgeon experience at China Medical University Hospital in Taichung, Taiwan. Between 2010 and 2016, 160 patients were diagnosed with upper and lower extremity lymphedema and were clinically staged according to the International Society of Lymphology (ISL) [20]. All of them underwent VLN transfer. However, in order to be included in this study, patients required at least a 2-year follow-up. Based on these criteria, we selected the VLN's used in our unit in the last 6 years: groin (G-VLN), supraclavicular (SC-VLN), and right gastroepiploic (RGE-VLN)

open and laparoscopic approach. In order to compare the different donor sites, we reviewed: lymphedema stage, etiology, limb affected, duration of symptoms, postoperative pain, numbness, intraoperative and postoperative complications, iatrogenic lymphedema, and flap harvest details. In addition, demographic data including gender, age, and BMI were obtained and summarized. Statistical analysis was performed with Student's *t* test, values of  $P < 0.05$  were considered significant. All calculations were done using SPSS V 20 for Mac OS X (IBM SPSS Statistics).

## RESULTS

From the 160 patients who underwent VLN transfer, 110 patients (28 male and 82 female) met inclusion criteria of 2-year follow-up. The average age was  $51.0 \pm 9.8$  years (range 17–78 years). A total of (n = 11) patients with primary and (n = 99) patients with secondary lymphedema were analyzed. A total of 41 patients were diagnosed with upper extremity lymphedema. One male patient had primary upper extremity lymphedema. The rest of the 40 patients with upper extremity lymphedema were secondary to breast cancer treatment. Patients with lower extremity lymphedema included primary (n = 10) and secondary to treatment of gynecologic cancer (n = 31), urologic conditions (n = 7), melanoma (n = 14), and trauma (n = 7). The mean body mass index (BMI) was  $27.2 \pm 2.6$  (range: 23–35). The mean duration of lymphedema symptoms was  $31.6 \pm 14.5$  months (range: 8–76 months).

Conflict of interest: None of the authors received any funds or has any financial interests to disclose.

\*Correspondence to: Pedro Ciudad, MD, PhD, Department of Plastic Surgery, China Medical University Hospital, 2 Yuh-Der Road, Taichung 40447, Taiwan. Fax: +886-4-2202 0038. E-mail: pciudad@hotmail.com

Received 11 June 2016; Accepted 15 June 2016

DOI 10.1002/jso.24349

Published online in Wiley Online Library (wileyonlinelibrary.com).

The number of VLN transfer was as follow: G-VLN (n = 20), SC-VLN (n = 54), RGE-VLN open (n = 19), and RGE-VLN laparoscopic (n = 17). Patients with upper extremities lymphedema underwent G-VLN (n = 10), SC-VLN (n = 11), RGE-VLN open (n = 11), and RGE-VLN laparoscopic (n = 9). Patients with lower extremities underwent G-VLN (n = 10), SC-VLN (n = 43), and RGE-VLN open (n = 8) and RGE-VLN laparoscopic (n = 8).

Regarding the mean operative time for flap harvest was: the G-VLN required  $92.5 \pm 12.7$  (range: 75–120) min, the SC-VLN  $78.7 \pm 24.9$  (range: 35–135) min, the RGE-VLN open approach  $92.6 \pm 9.8$  (range: 80–110) min, and the laparoscopic RGE-VLN  $33.1 \pm 4.4$  (range: 25–41) min.

The average hospital length of stay for the G-VLN was  $12.3 \pm 1.5$  (range: 10–14) days, for the SC-VLN was  $13.4 \pm 2.4$  (range: 10–19) days, for the open RGE-VLN was  $13.1 \pm 1.2$  (range: 10–15) days, and for the laparoscopic RGE-VLN was  $5.7 \pm 0.7$  (range: 5–7) days.

Patients' mean follow-up time was  $31.4 \pm 5.9$  (range: 24–40) months for the G-VLN,  $33.0 \pm 7.0$  (range: 24–49) months for the SC-VLN,  $26.6 \pm 2.8$  (range: 24–35) months for the RGE-VLN open approach, and  $25.6 \pm 1.8$  (range: 24–29) months for the RGE-VLN laparoscopic approach.

In terms of complications, one patient presented with lymphatic leakage at the donor site after a G-VLN harvest. However, the patient was treated successfully by ligation of lymphatic channels, local compression, and drain placement for approximate 14 days. Another patient presented with lymph leakage after SC-VLN transfer. However, this patient was managed conservatively with compression. One patient presented with a hematoma in the immediate postoperative period after the SC-VLN. This required return to the operating room for ligation of the transverse cervical artery (TCA).

During the follow-up period, no other patients presented with any signs or symptoms of donor site lymphedema, lymphorrhea, postoperative cellulitis, or wound complications. Results are summarized in detail in Tables I and II.

## DISCUSSION

The most common physiologic procedures for the treatment of lymphedema are lymphatic-venous anastomosis (LVA) [21–24] and VLN transfer [1–12]. In the last several years, VLN transfer has been gaining popularity as a promising option for the surgical treatment of moderate to advanced lymphedema [6–10,11].

VLN transfer is currently one of the most common procedures performed in our department [1,7,10–12,25–29]. Based on the senior's author experience, we describe the technical details and compare donor site morbidity of the three most common VLN used in our department.

### (A) The Vascularized Groin Lymph Node Flap

The vascularized groin lymph node flap was the first VLN described in the literature [30]. Despite its promising early and long-term results [6], concerns regarding postoperative donor site lymphedema and adequacy of the G-VLN vessels have limited its popularity [13,19]. The G-VLN can be based either on the superficial circumflex iliac artery (SCIA), the superficial inferior epigastric artery (SIEA), or a small, unnamed medial branch of the femoral artery (MBFA).

Based on our experience, some of the pitfalls encountered during flap harvest include: (i) Due to the small vascular diameter and a short

TABLE I. Data of Patients Who Underwent Vascularized Lymph Node Transfer for Treatment of Extremity Lymphedema

	Supraclavicular VLN			Groin VLN			Right gastroepiploic VLN					
							Open			Laparoscopic		
	Mean	SD	Range	Mean	SD	Range	Mean	SD	Range	Mean	SD	Range
Age	52.0	13.0	18.0–78.0	43.2	11.5	17.0–61.0	53.3	8.7	34.0–65.0	55.7	6.2	44.0–68.0
Sex												
Female		34			13			18			17	
Male		20			7			1			0	
BMI	27.7	3.0	23.0–35.0	26.1	2.5	22.6–31.0	27.3	2.4	24.0–31.0	27.6	2.8	23.0–32.4
Diagnosis												
Primary		8			2			1			0	
Secondary		46			18			18			17	
Breast cancer relative lymphedema		11			10			10			9	
Gynecology cancer relative lymphedema		17			0			7			7	
Urology cancer relative lymphedema		7			0			0			0	
Melanoma		5			8			1			0	
Traumatic		6			0			0			1	
Stage of lymphedema												
Stage II		19			11			8			9	
Stage III		35			9			11			8	
Limb affected												
Upper limb		11			10			11			9	
Lower limb		43			10			8			8	
Bilateral lower limb lymphedema		4			2			0			0	
Duration symptoms (months)	27.5	16.9	12.0–76.0	24.7	15.3	8.0–65.0	29.6	12.6	10.0–52.0	35.9	13.1	16.0–61.0
Hospital stay	13.4	2.4	10.0–19.0	12.3	1.5	10.0–14.0	13.1	1.2	10.0–15.0	5.7	0.7	5.0–7.0
Flap harvest operating time (min)	78.7	24.9	35.0–135.0	92.5	12.7	75.0–120.0	92.6	9.8	80.0–110.0	33.1	4.4	25.0–41.0
Complications												
Iatrogenic lymphedema		0			0			0			0	
Hematoma		Postoperative (1)										
Lymphatic leakage		Postoperative (1)			Intraoperative (1)							
Wound infection		0			0			0			0	
Seroma		0			0			0			0	
Dehiscence		0			0			0			0	
Follow up (months)	33.0	7.0	24.0–49.0	31.4	5.9	24.0–40.0	26.6	2.8	24.0–35.0	25.6	1.8	24.0–29.0

VLN, vascularized lymph node; SD, standard deviation.

TABLE II. Supraclavicular, Groin, and Right Gastroepiploic Vascularized Lymph Node Flaps Anatomical Characteristics

Supraclavicular VLN	54 (n)	100.0 (%)	Groin VLN	20 (n)	100.0 (%)	Right gastroepiploic VLN	36 (n)	100.0 (%)
Arterial pedicle								
Thyrocervical trunk	49	90.7	SCIA	14	70.0	RGE	36	100.0
Subclavian branch	5	9.3	MBFA	6	30.0			
Arterial flow								
Antegrade	52	96.3	Antegrade SCIA	12	60.0	Antegrade	36	100.0
Retrograde	2	3.7	Retrograde SCIA	2	10.0			
Vein pedicle								
Concomitanae vein	54	100.0	Concomitanae vein	20	100.0	Concomitanae vein	36	100.0
IJV branch	50	92.6	Greater saphenous branch	20	100.0			
Both	50	92.6	Both	20	100.0			
Skin paddle	23	42.6		19	95.0			
Nerve anastomosis								
Yes	10	18.8						
No	44	81.2						
Pain resolve								
6 months	35	64.8						
12 months	52	96.3						
Persist	2	3.7						
Numbness resolve								
6 months	25	46.3						
12 months	47	87.0						
Persist	3	5.6						

n, number of patients.

pedicle of the SCIA, we include a small “cuff” measuring approximate between 1 and 1.2 mm from the femoral artery at the origin of SCIA. This cuff allows us to perform the anastomosis faster and improves its patency rate [31]. (ii) When the SCIA is not suitable for microvascular anastomosis, the flap should be re-designed and based on a different vessel, such as the MBFA or SIEA [32]. Prior reports have shown that the groin area has different subset of lymph nodes [33–34]. Keeping this in mind, it provides key anatomical landmarks in order to avoid the risks of donor site lymphedema and helps harvest adequate VLN for transfer. When using the MBFA, care should be taken to avoid harvesting the sentinel lymph nodes in the groin, since they will preserve the lymphatic drainage of the lower extremity and avoid iatrogenic donor site lymphedema [13]. In this series, when the G-VLN was harvested, we used the SCIA in 70% of patients and the MBFA in 30% of the patients for an antegrade vascularization. (iii) However, when the SCIA or MBFA were not suitable for anastomosis, the retrograde vascularization of SCIA was performed using the lateral part of the SCIA to vascularize the flap in a retrograde fashion. In one case, it was used when the lymph nodes were adjacent to the femoral artery, since the lymph nodes would decrease the length of the vascular stump during the microsurgical anastomosis if the flap had been harvested with an antegrade vascularization. In one other patient, the retrograde vascularization was used when the caliber of the SCIA decreased toward its origin from the femoral artery. (iv) For the venous anastomosis, we always include two veins within the flap, the concomitant vein and a branch of the greater saphenous vein, or another suitable cutaneous vein. We believe that having two draining routes during lymph node transfer will aid increase the lympho-venous outflow from the flap into the systemic circulation [35]. The inclusion of skin paddles in VLN transfers has aided in postoperative monitoring, flap harvest, and relieving tension over the flap at the time of inset. In our series when using the G-VLN, we removed the skin component in only one case, due to the increased thickness of the flap. Regarding complications, we only encountered one case of lymphatic leakage after G-VLN flap harvest (Fig. 1A). This was most likely due to injury of an abnormal variation of the lymphatic channels in the groin area. This was treated by ligation and clipping of leaking lymphatic channels and placing appropriate drains until no lymph fluid was seen in the postoperative period. After a 2-year follow-up, the patient did not present with any clinical signs or symptoms of lymphedema from the

donor site (Fig. 1B) confirmed by postoperative lymphoscintigraphy (Fig. 1C).

All these techniques were applied during G-VLN in order to prevent problems during flap harvest and to avoid any potential complications or iatrogenic lymphedema.

### (B) The Vascularized Supraclavicular Lymph Node Flap

In 2012, Becker et al. described the first cervical VLN also known as the supraclavicular lymph node flap (SC-VLN), which is based on the TCA [5]. Later, our group reported a series of clinical outcomes in patients who were treated with this flap for lower extremity lymphedema [7]. During our experience, some of the pearls used in order to avoid complications were: (i) All flaps were harvested from the right side of the neck to avoid potential injury to the thoracic duct. (ii) All flaps were based on the TCA. For flap harvest the transverse cervical vessels are identified within the pre scalene adipose tissue. Careful dissection will ensure that the artery is not separated from the overlying adipose tissue, which include the lymph nodes. (iii) We experienced two cases of anatomical variation of the TCA; in both cases, the TCA was running distally and deep, so the proximal and medial part of the arterial pedicle was not included during flap harvest. This made us redesign the flap in a retrograde fashion in order to preserve good blood supply. In our series, the concomitant transverse cervical vein (TCV) is also included with the flap and its location is constant, posterolateral, and superficial to the TCA. (iv) The other venous anastomosis was performed with one branch of the external jugular vein (EJV). Always two-vein anastomoses were performed to increase the lymphovenular bypass of the flap and to prevent flap congestion.

Of note, a prominent cutaneous sensory nerve in all our cases traversed the SC-VLN. Most often, dissecting the nerve and resecting the superficial tissue can preserve this nerve, as the majority of the lymph nodes are deeper. (v) In obese patients with an increase amount of fat tissue in the neck, a deep dissection is required. However, in some cases, when the supraclavicular nerve goes through the SC-VLN, we divide the nerve in order to include the deepest lymph nodes and to avoid harvesting a bulky flap.

When the supraclavicular nerve is divided, reanastomosis is recommended since it can lead to pain and numbness in this region. Our experience indicates that primary repair resulted in faster sensory

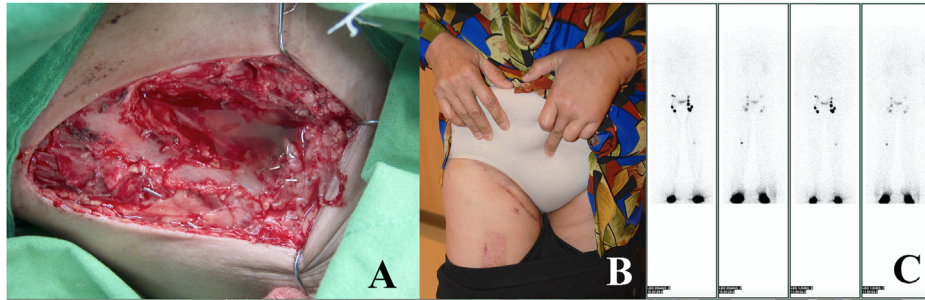


Fig. 1. Patient with left upper extremity lymphedema who underwent vascularized right groin lymph node transfer. (A) Picture shows lymph leakage after flap harvest. Clip and ligation was performed. JP drain was placed and maintained for 6 days. (B) Picture shows at 24 months of follow-up no donor site morbidity from donor site. (C) Postoperative lymphoscintigraphy confirmed no iatrogenic lymphedema over the donor site at 24 months of follow-up.

recovery leaving no long-term sequela (Table II). However, further studies to confirm these findings are still necessary.

One of the controversies when using this flap is regarding the skin paddle. The use of skin paddles facilitates the inset of the flap at the recipient site. However, when the SC-VLN was raised with a skin paddle, we have noticed that it was not reliable due to venous congestion and had to be removed intraoperatively in 20% of the cases.

Currently, there is only one report showing iatrogenic lymphedema after SC-VLN harvest [17]. However, in this series, we did not encounter any cases of iatrogenic lymphedema of the upper limb. Even though all SC-VLNs were harvested from the right side of the neck to avoid possible injury to the thoracic duct, we encountered one patient with donor site lymphorrhea (Fig. 2A), which was managed conservatively with compression for 14 days. During a 2-year follow-up, this patient had no signs or symptoms of upper limb lymphedema (Fig. 2B and C). Another patient had a donor site hematoma, which was detected 30 min after surgery. The patient was brought back to the operating room and required ligation at the origin of the TCA.

### (C) The Vascularized Right Gastroepiploic Lymph Node Flap

The first reported experience using the omental flap to treat chronic lymphedema was done by Goldsmith et al. [36]. With the use of microvascular techniques, a free omental flap can be used as a source for VLN transfer. The use of the isolated vascularized right gastroepiploic

lymph node flap (RGE-VLN) based on the right gastroepiploic vessels can be harvested by open, laparoscopically, or robotic techniques [10–12].

In our experience, the RGE-VLN has a consistent vascular anatomy and large caliber vessels, which makes it a very reliable flap to harvest. However, this flap has only one vein for drainage.

When the RGE-VLN was harvested by open approach, it was performed using a supraumbilical incision. During dissection, we try to minimize the use of electrocautery, and use only suture ligation in order to prevent lymphatic leakage or hematoma from the donor site and from the flap after inset. However, some of the possible disadvantages of the open approach are postoperative pain, increased risk of wound infection, intrabdominal organ damage, adhesions, hernia or bulging of the abdominal wall, and supraumbilical scar. Prior exploratory laparotomies can make the dissection more challenging due to the amount of adhesion, which might increase the risk of omental tissue damage.

The RGE-VLN via laparoscopic approach is ideal for patients with a high BMI, has less risk of hernia or bulging of the abdominal wall, decreases the amount of postoperative pain, and hospital length of stay [11]. In our experience, some of the surgical pearls using the laparoscopic approach are the following: (i) After the pedicle is identified, dissection should be performed trying to preserve as much as omental tissue as possible around the vascular pedicle and minimizing the risk of damage to the fine lymphatic channels, and lymph nodes surrounding the pedicle. (ii) The RGE-VLN should be dissected close to its origin in order to preserve an adequate pedicle length for microsurgical anastomosis.

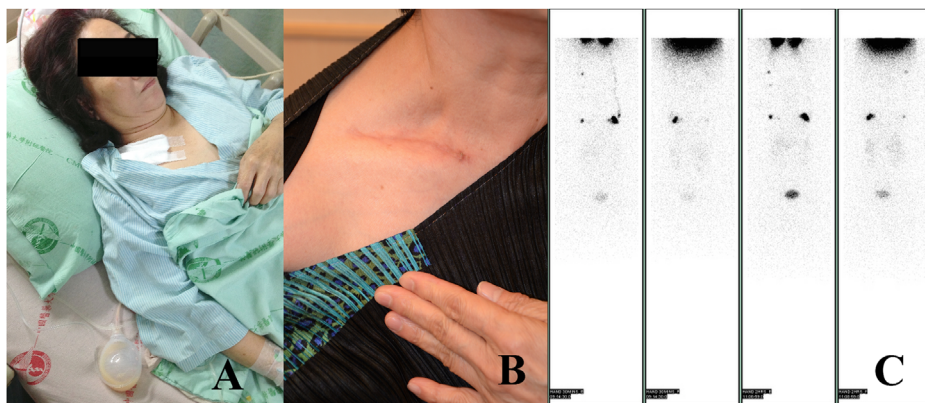


Fig. 2. A 51-year-old female with right lower extremity lymphedema after total hysterectomy, inguinal lymph node dissections, and postoperative radiotherapy. She underwent a vascularized supraclavicular lymph node transfer to the ankle. However, the 1st day after SC-VLN transfer patient develop lymph leakage from its donor site (A). This patient was managed conservative using compression and suction drain for 14 days. At 24-month follow-up, the patient did not have any symptom of donor site and right upper limb lymphedema clinically (B) and by lymphoscintigraphy (C) post SC-VLN transfer.

However, care should be taken close to the origin of the pedicle, to prevent injuries to the pancreas and/or duodenum as well as their blood supply. (iii) Blunt and sharp dissection with suture ligation is always preferred over electrocautery dissection, since high instrument temperatures or cauterizing close to the pedicle or lymphatic channels may compromise the vascularity of the transferred flap.

In addition, when the RGE-VLN is extended beyond the midpoint of the greater curvature of the stomach, it can provide a larger flap, giving the option to split the RGE-VLN in to two equal portions. This will potentiate its physiologic mechanism (pump action) [4,35] by inseting the flap at different levels of the affected limb in one stage procedure. This in turn, might increase the lymphatic drainage, leading to a more uniform improvement across the entire affected extremity while avoiding different donor sites with its possible complications. Also the double flap might be used in patients with bilateral extremity lymphedema.

Regarding donor site lymphedema (chyloperitoneum), there are no reports in the literature showing iatrogenic intra-abdominal lymphedema following surgical resection of the greater omentum and its lymph nodes. The omental flap's major disadvantage is laparotomy-associated morbidity. Complications reported associated with laparoscopy harvest of this flap include injuries of the pedicled, partial graft necrosis, incisional hernia, peritonitis, hemorrhage, and wound infection [38]. The laparoscopic harvest allowed to harvest the omental flap with less donor site morbidity [11,37,38]. And during the follow-up period, we also did not encounter any cases of iatrogenic intra-abdominal lymphedema or any gastrointestinal complications by physical exam, or CT-scan imaging after RGE-VLN harvest. Based on our experience, we quickly transitioned from an open to a laparoscopic approach due to the significant benefits of a minimally invasive intervention [10,11].

Even though we try to minimize donor site morbidity and avoid the use of split-thickness skin graft (STSG), the majority of the RGE-VLN required a small STSG to avoid tension, and compression on the flap and its pedicle.

Our major concern with VLN transfer surgery for the treatment of extremity lymphedema has always been donor site morbidity and potential donor site iatrogenic lymphedema. In our last 6 years, we have treated more than 160 patients using this technique with different types of VLNs, and the results have been promising and with very few minor complications [10–12].

Currently, the RGE-VLN is our flap of choice for the treatment of extremity lymphedema due to its lymphatic properties and promising results. In addition, when the flap is harvested laparoscopically, decreases postoperative pain, hospital length of stay, and donor site morbidity (Table I) [11]. However, when the RGE-VLN is not available due to previous laparotomies, extensive intrabdominal adhesions, or any other intrabdominal comorbidities, our preference is to choose the SC-VLN for lower extremity lymphedema or the G-VLN for upper extremity lymphedema.

The use of VLN transfer for the treatment of lymphedema is a promising technique. The main weakness of this paper is the lack of imaging techniques to localize and count the number of lymph nodes transferred with each flap. However, based on this clinical experience and using the technical points described, we believe that we can prevent and minimize donor site complications during flap harvest. Further studies with larger number of patients and longer follow-up are required to improve our current surgical approaches, and to help minimize donor site complications.

## CONCLUSION

In lymph node flap transfer surgery, correct flap selection and surgical experience are imperative in order to reduce donor site morbidity, iatrogenic lymphedema, and to improve final outcomes.

Based on our experience the RGE-VLN transfer reduces donor site morbidity, hospital length of stay, and operative time especially when harvested laparoscopically. However, depending on surgeon's expertise and preference, other type of VLN flaps are also good surgical options.

## ACKNOWLEDGMENTS

All authors hereby declare not to have any potential conflict of interests and not to have received funding for this work from any of the following organizations: National Institutes of Health (NIH); Wellcome Trust; Howard Hughes Medical Institute (HHMI); and other(s). Each author participated sufficiently in the work to take public responsibility for the content.

## REFERENCES

1. Chen HC, O'Brien BM, Rogers IW, et al.: Lymph node transfer for the treatment of obstructive lymphoedema in the canine model. *Br J Plast Surg* 1990;43:578–586.
2. Ito R, Suami H: Overview of lymph node transfer for lymphedema treatment. *Plast Reconstr Surg* 2014;134:548–556.
3. Raju A, Chang DW: Vascularized lymph node transfer for treatment of lymphedema: A comprehensive literature review. *Ann Surg* 2014;261:1013–1023.
4. Granzow JW, Soderberg JM, Kaji AH, et al.: Review of current surgical treatments for lymphedema. *Ann Surg Oncol* 2014; 21:1195–1201.
5. Becker C, Vasile JV, Levine JL, et al.: Microlymphatic surgery for the treatment of iatrogenic lymphedema. *Clin Plast Surg* 2012; 39:385–398.
6. Lin CH, Ali R, Chen SC, et al.: Vascularized groin lymph node transfer using the wrist as a recipient site for management of postmastectomy upper extremity lymphedema. *Plast Reconstr Surg* 2009;123:1265–1275.
7. Sapountzis S, Singhal D, Rashid A, et al.: Lymph node flap based on the right transverse cervical artery as a donor site for lymph node transfer. *Ann Plast Surg* 2013;73:398–401.
8. Cheng MH, Huang JJ, Nguyen DH, et al.: A novel approach to the treatment of lower extremity lymphedema by transferring a vascularized submental lymph node flap to the ankle. *Gynecol Oncol* 2012;126:93–98.
9. Barreiro GC, Baptista RR, Kasai KE, et al.: Lymph fasciocutaneous lateral thoracic artery flap: Anatomical study and clinical use. *J Reconstr Microsurg* 2014;13.
10. Ciudad P, Kiranantawat K, Sapountzis S, et al.: Right gastroepiploic lymph node flap. *Microsurgery* 2014;35:496–497.
11. Ciudad P, Maruccia M, Socas J, et al.: The laparoscopic right gastroepiploic lymph node flap transfer for upper and lower limb lymphedema: Technique and outcomes. *Microsurgery* 2015; doi: 10.1002/micr.22450 [Epub ahead of print].
12. Ciudad P, Date S, Lee MH, et al.: Robotic harvest of a right gastroepiploic lymph node flap. *Arch Plast Surg* 2016;43:210–212.
13. Dayan JH, Dayan E, Smith ML: Reverse lymphatic mapping: A new technique for maximizing safety in vascularized lymph node transfer. *Plast Reconstr Surg* 2015;135:277–285.
14. Sulo E, Hartiala P, Viitanen T, et al.: Risk of donor-site lymphatic vessel dysfunction after microvascular lymph node transfer. *J Plast Reconstr Aesthet Surg* 2015;68:551–558.
15. Azuma S, Yamamoto T, Koshima I: Donor-site lymphatic function after microvascular lymph node transfer should be followed using indocyanine green lymphography. *Plast Reconstr Surg* 2013; 131:443e–444e.
16. Viitanen TP, Mäki MT, Seppänen MP, et al.: Donor-site lymphatic function after microvascular lymph node transfer. *Plast Reconstr Surg* 2012;130:1246–1253.
17. Massey MF, Gupta DK: The incidence of donor-site morbidity after transverse cervical artery vascularized lymph node transfers: The need for a lymphatic surgery national registry. *Plast Reconstr Surg* 2015;135:939e–940e.

18. Vignes S, Blanchard M, Yannoutsos A, et al.: Complications of autologous lymph-node transplantation for limb lymphoedema. *Eur J Vasc Endovasc Surg* 2013;45:516–520.
19. Pons G, Masia J, Loschi P, et al.: A case of donor-site lymphoedema after lymph node-superficial circumflex iliac artery perforator flap transfer. *J Plast Reconstr Aesthet Surg* 2014;67:119–123.
20. International Society of Lymphology The diagnosis and treatment of peripheral lymphedema. Consensus document of the international society of lymphology. *Lymphology* 2003;36:84–91.
21. Chang DW, Suami H, Skoracki R: A prospective analysis of 100 consecutive lymphovenous bypass cases for treatment of extremity lymphedema. *Plast Reconstr Surg* 2013;132:1305–1314.
22. Campisi C, Boccardo F, Zilli A, et al.: Long-term results after lymphatic-venous anastomoses for the treatment of obstructive lymphedema. *Microsurgery* 2001;21:135–139.
23. Yamamoto T, Chen WF, Yamamoto N, et al.: Technical simplification of the supermicrosurgical side-to-end lymphaticovenular anastomosis using the parachute technique. *Microsurgery* 2015;35:129–134.
24. Boccardo F, Casabona F, DeCian F, et al.: Lymphatic microsurgical preventing healing approach (LYMPHA) for primary surgical prevention of breast cancer-related lymphedema: Over 4 years follow-up. *Microsurgery* 2014;34:421–424.
25. Sapountzis S, Ciudad P, Lim SY, et al.: Modified Charles procedure and lymph node flap transfer for advanced lower extremity lymphedema. *Microsurgery* 2014;34:439–447.
26. Yeo MS, Lim SY, Kiranantawat K, et al.: A comparison of vascularized cervical lymph node transfer with and without modified Charles' procedure for the treatment of lower limb lymphedema. *Plast Reconstr Surg* 2014;134:171–172.
27. Ciudad P, Yeo MS, Sapountzis S, et al.: Microsurgical debulking procedure after free lymph node flap transfer. *Microsurgery* 2014;34:670–671.
28. Ciudad P, Date S, Orfaniotis G, et al.: Delayed grafting for banked skin graft in lymph node flap transfer. *Int Wound J* 2016; doi: 10.1111/iwj.12570 [Epub ahead of print].
29. Nicoli F, Constantinides J, Ciudad P, et al.: Free lymph node flap transfer and laser-assisted liposuction: A combined technique for the treatment of moderate upper limb lymphedema. *Lasers Med Sci* 2015;30:1377–1385.
30. Shesol BF, Nakashima R, Alavi A, et al.: Successful lymph node transplantation in rats, with restoration of lymphatic function. *Plast Reconstr Surg* 1979;63:817–823.
31. Lim SY, Yeo MS, Nicoli F, et al.: End-to-patch anastomosis for microvascular transfer of free flaps with small pedicle. *J Plast Reconstr Aesthet Surg* 2015;68:559–564.
32. Ciudad P, Orfaniotis G, Socas J, et al.: Technical considerations to avoid microvascular complications during groin lymph node free flap transfer. *Arch Plast Surg* 2015;42:650–652.
33. Zhang H, Chen W, Mu L, et al.: The distribution of lymph nodes and their nutrient vessels in the groin region: An anatomic study for design of the lymph node flap. *Microsurgery* 2014;34:558–561.
34. Scaglioni MF, Suami H: Lymphatic anatomy of the inguinal region in aid of vascularized lymph node flap harvesting. *J Plast Reconstr Aesthet Surg* 2015;68:419–427.
35. Cheng MH, Huang JJ, Wu CW, et al.: The mechanism of vascularized lymph node transfer for lymphedema: Natural lymphaticovenous drainage. *Plast Reconstr Surg* 2014;133:192.
36. Goldsmith HS: Long term evaluation of omental transposition for chronic lymphedema. *Ann Surg* 1974;180:847–849.
37. Salz R, Stowers R, Smith M, et al.: Laparoscopically harvested omental free flap to cover a large soft tissue defect. *Ann Surg* 1993;217:542–546.
38. Garderen Van, Wiggers TH, Van Geel AN: Complications of the pedicled omentoplasty. *Neth J Surg* 1991;43:1171–1174.

## SYNOPSIS

The aim of this study is to discuss the pearls and pitfalls for lymph node flap harvest and to compare donor site morbidity and complications at donor site following vascularized lymph node transfer with the most common flaps used in our unit in 110 patients.